

Endobutton technique for the treatment of acute acromioclavicular joint dislocations

Akut akromioklaviküler eklem çıkıklarında endobutton ile tesbit yöntemi

Raif Özden¹, Vedat Uruç¹, İbrahim Gökhan Duman¹, Yunus Dođramacı¹,
Aydın Kalacı¹, Erkam Kömürcü²

ABSTRACT

Objective: Acromioclavicular (AC) joint dislocation is a common injury frequently affecting young athletes. The aim of this study is to evaluate postoperative functional results in cases diagnosed with acute AC joint dislocation stabilized with endobutton system.

Methods: This fixation procedure has been applied on 10 patients. Indications of the technique included: a grade V AC joint dislocation (7 patients), and grade III AC joint dislocation (3 patient) according to Rockwood classification. The coracoclavicular (CC) interval and AC joint were reduced using two endobuttons. One endobutton was fitted on the clavicle and the second was placed at the undersurface of the coracoid. Outcomes were assessed with the Constant shoulder score and visual analog pain scale.

Results: All the patients had powerful intraoperative fixation. Immediately after surgery, and 6 weeks, and 1 year postoperative radiographs showed adequate reduction of the CC distance and the AC joint. The mean Constant shoulder score was 89 (88–92) in the injured shoulder and 90 (88–93) in the uninjured shoulder. There was no statically significant difference between the injured and normal shoulder in terms of Constant shoulder score and there was no complication during the process.

Conclusion: This technique is a safe and effective method for providing fixation for the AC joint.

Key words; Acromioclavicular joint, dislocations, surgery, endobutton

ÖZET

Amaç: Akromioklaviküler eklem çıkıkları daha çok genç atletlerde sık görülen bir yaralanmadır. Bu çalışmanın amacı endobutton sistemi ile tespit edilmiş akut akromioklaviküler eklem çıkıklarının postoperatif fonksiyonel sonuçlarını değerlendirmektir.

Yöntemler: Bu tespit yöntemi 10 hastaya uygulandı. Rockwood sınıflamasına göre yedi has-tada tip V, üç hastada tip III çıkık vardı. Korakoklaviküler aralık ve akromioklaviküler eklem iki endobutton kullanılarak redükte edildi. Bir endobutton klavikulanın üzerine ikincisi korakoid çıkıntının altına yerleştirildi. Sonuçlar Constant omuz skoru ve vizüel analog skala ile değerlendirildi.

Bulgular: Tüm hastaların intraoperatif olarak fiksasyonunun sağlam olduğu görüldü. Ameliyattan hemen sonra, 6. haftada ve 1 yıl sonra çekilen grafilerde, korakoklaviküler aralık ve akromioklaviküler eklem yeterli derecede redükte olduğu tespit edildi. Ortalama Constant omuz skoru ameliyatlolu omuzda 89 (88-92), sağlam omuzda ise 90 (88-93) olarak bulundu. Constant omuz skoru ile değerlendirildiğinde akromioklaviküler çıkık olan taraf ile normal taraf arasında anlamlı istatistiksel fark bulunamadı ve herhangi bir komplikasyonla karşılaşılmadı.

Sonuçlar: Bu metod akromioklaviküler eklem tesbiti için güvenli ve etkin bir yöntemdir.

Anahtar kelimeler: Akromioklaviküler eklem, çıkıklar, cerrahi, endobutton

INTRODUCTION

Acromioclavicular (AC) joint injuries constitute about 9% of all shoulder injuries [1]. AC joint dis-

location is a prevalent injury frequently affecting young athletes. Most of these athletes sustain high grade injuries necessitating surgical treatment to allow them to return to their sport activities. High

¹ Mustafa Kemal University Faculty of Medicine, Department of Orthopaedics and Traumatology, Antakya, Hatay, Turkey

² Çanakkale Onsekiz Mart University School of Medicine, Department of Orthopaedics and Traumatology, Çanakkale, Turkey

Yazışma Adresi /Correspondence: Raif Özden,

Mustafa Kemal Univ. Faculty of Medicine, Dept. of Orthopaedics - Traumatology, Hatay, Turkey; Email: raifozden@gmail.com

Geliş Tarihi / Received: 04.02.2014, Kabul Tarihi / Accepted: 24.04.2014

Copyright © Dicle Tıp Dergisi 2014, Her hakkı saklıdır / All rights reserved

grade dislocations if left untreated will always cause a painful joint and significant loss of strength in the affected shoulder. Many surgical techniques have been described for the treatment of AC joint injuries, but none of them is the gold standard [2-4]. The application of this technique that if the joint is reduced acutely and retained as reduced during the healing period, the natural ligaments will heal repairing the stability of the AC joint. AC joint dislocation including different types of injuries to the AC and coracoclavicular (CC) ligaments. Most frequently, the mechanism of this injury is a direct force on the lateral aspect of the shoulder with the arm in an abducted position. This report describes sufficient results obtained from a surgical procedure using endobutton system.

METHODS

This fixation procedure was performed with 10 patients (6 male, 4 female). The dominant limb was involved in 4 of 10 cases. Intraoperative satisfactory reduction and fixation were confirmed both clinically and radiologically with the x-ray image intensifier. Postoperative radiographs performed at immediately after surgery, and 6 weeks, and 1 year demonstrated satisfactory reduction of the CC interval and the AC joint in all the patients.

Between 2009 and 2011, 10 cases were diagnosed with acute AC dislocation. Mean age was 36.8 years (range, 25–60 years). The endobutton system was used for stabilization (Figure 1). The mean follow-up was 16-month (12-24 months). The AC and CC ligaments were ruptured completely in acute AC joint dislocation. Indications of the technique included: a grade V AC joint dislocation (7 patients), and grade III AC joint dislocation (3 patient) according to Rockwood classification. All of the patients were operated within same week of their injury. The exclusion criteria were the cases in which conservative treatments and other surgical techniques had been used. It was decided to reconstruct the CC ligaments with an endobutton fixation system.

The medial and lateral borders of the coracoid process were determined. A 4-mm endobutton drill bit guide was inserted to the superior clavicle about

2 cm from AC joint to the base of the coracoid process. Using a 4-mm cannulated drill over the pin and through the clavicle and coracoid, we drilled bone tunnels, being careful not to damage the tissues under coracoid process with drill bit or fracture the coracoid. A retractor can also be placed inferior to the coracoid process to assure that the drill bit does not go too deep below the coracoid process. It is important that the course of the drill is in the center of the superior surface of the coracoid process to attain optimal fixation. The length of CC interval was measured after AC joint reduction and appropriate two endobuttons were used. As we know minimum 10 mm additional drilling is needed to allow the endobutton device to be rotated at the femoral site. Because of the flexibility of the AC joint we did not see any loss of reduction after rotating the endobutton. Two endobuttons were used in order to achieve this stability (Figure 2). One of them was placed on the clavicle and the second was fitted undersurface of the coracoid (Figure 3).

Outcomes were assessed with the visual analog pain scale and Constant shoulder score. We compared injured shoulder with the normal shoulder using Mann–Whitney U test. Postoperatively, a sling was performed for 3 weeks with suggestion of gentle range of motion up to the shoulder level, flexion and extension of the elbow, and pendulum exercises of the shoulder. Light duties were permitted from 4 to 12 weeks, and heavy duties resumed from 3 months further.

RESULTS

Preoperative average pain score was 5.5 ± 0.7 mm, and postoperatively the average pain score was 2.0 ± 0.5 mm measured with visual analog scale. There was a statistically significant difference between the preoperative and postoperative pain VAS scores ($p < 0.05$). The mean Constant shoulder score was 89 (88–92) in the injured shoulder and 90 (88–93) in the uninjured shoulder. There was no statistically significant difference between the two shoulders and results were considered as an excellent in terms of Constant shoulder score and there was no complication during the process.

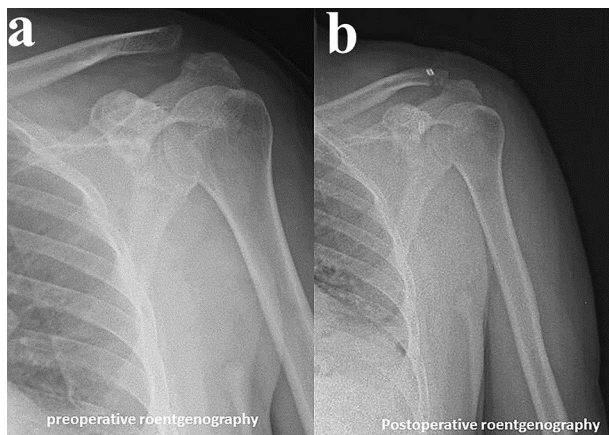


Figure 1: Grade III acromioclavicular joint dislocation stabilized with endobutton system. **a:** Preoperative roentgenography, **b:** Postoperative roentgenography

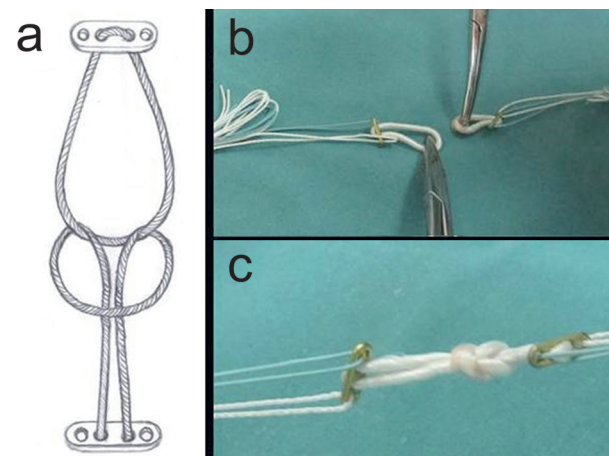


Figure 2: Two endobuttons were used for stabilizing the joint. **a:** Schematic representation of tying two endobuttons to each other, **b:** Two endobutton devices with their loop, **c:** Tied endobuttons

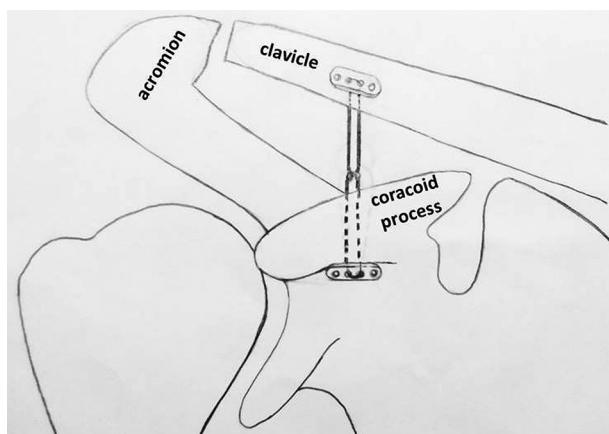


Figure 3: Illustration of our fixation technique with two endobuttons

DISCUSSION

A primary principle in the treatment of acute AC joint dislocations is to repair mechanical stability and joint congruity as accurately as possible to maintain appropriate conditions for the development of rigid scar tissue healing. CC fixation is generally favored over AC joint fixation because of its superior results, lower complication rates, and decreased late AC joint arthrosis [5,6]. Effectively, the ability to obtain a functional reconstruction of the joint anatomy with surgery might lessen the rate of secondary osteoarthritis and prevent persistent discomfort [7].

AC stability is maintained by the CC ligaments. The AC capsule and ligaments also stabilize the joint. According to Rockwood classification, there are six types of AC joint dislocations. Many researches have supported nonsurgical management for Rockwood’s grade I and II injuries, but there is a general consensus that grade IV, V, and VI injuries are best treated with surgical management [8]. The management of grade III injuries remains controversial. Nonetheless, surgical treatment is often chosen to allow more rapid rehabilitation and to enable an early return to daily activity in the young, active patients, high level athletes and manual workers [9].

Currently, there are four main surgical treatment options for the dislocated AC joint: (1) excision of the distal clavicle with or without CC ligament repair with suture or fascia, or coracoacromial ligament transfer [10,11], (2) primary AC joint fixation (with screws, pins, hook plates) with or without ligament reconstruction or repair [12], (3) CC interval fixation with or without AC ligament repair or reconstruction [13], and (4) muscle transfers with or without excision of the distal part of the clavicle [14].

The various techniques described above show the fact that the ideal procedure to treat a symptomatic AC joint dislocation remains controversial. Choosing the right procedure for a specific patient population is important for the successful management of the injury [1]. Despite modern arthroscopically assisted and minimally invasive treatment options for anatomic repair of the CC ligaments, there is still no gold standard treatment for AC joint dislocations. Arthroscopic treatment is a minimally

invasive approach, has the option of examining the glenohumeral joint for associated lesions and ultimately managing them, and has the benefits of not exposing the patient or surgeon to radiation [15]. Furthermore, it delivers good clinical and aesthetic results in the treatment of acute AC joint lesions [16]. The short to midterm results of arthroscopic stabilization techniques show an at least equal outcome to those presented in open surgery [17]. However, it has a long learning curve. All orthopedic surgeons can not perform this procedure. As recently described, minimal invasive techniques, using anchors or buttons with or without tendon grafts may be the best options in the future. At the present time, open surgical techniques like reconstructions with absorbable or non-absorbable sutures are still in use for acute AC joint dislocations and show sufficient and excellent results, even though mild redislocations are reported [18-21]. Wei et al. revealed fifteen cases who had undergone surgical management using triple endobutton technique. The mean visual analog scale scores of all patients was 0.2 (range, 0-2) at the final evaluation. Preoperatively, the score was 5.5 (range, 4-7). There was a significant difference between the preoperative and postoperative pain visual analog scale scores [22].

In conclusion, this technique is a safe and effective method for providing fixation for the AC joint. We suppose that this technique provided sufficient stability to prevent a vertical redislocation during the healing period.

REFERENCES

- Mazzocca AD, Arciero RA, Bicos J. Evaluation and treatment of acromioclavicular joint injuries. *Am J Sports Med* 2007;35:316-329.
- Collins DN. Disorders of the acromioclavicular joint. In: Rockwood CA Jr, Matsen FA 3rd, Wirth MA, Lippitt SB, editors. *The shoulder*. Philadelphia: Saunders (Elsevier); 2009. p. 453-526.
- Galatz LM, Williams GR Jr. Acromioclavicular joint injuries. In: Bucholz RW, Heckman JD, editors. *Rockwood and Green's fractures in adults*. Philadelphia: Lippincott Williams & Wilkins; 2001. p. 1209-1244.
- Simovitch R, Sanders B, Ozbaydar M, et al. Acromioclavicular joint injuries: diagnosis and management. *J Am Acad Orthop Surg* 2009;17:207-219.
- Smith MJ, Stewart MJ. Acute acromioclavicular separations. *Am J Sports Med* 1979;7:62-71.
- Taft TN, Wilson FC, Oglesby JW. Dislocation of the acromioclavicular joint: An end result study. *J Bone Joint Surg* 1987;69A:1045-1051.
- Calvo E, Lopez-Franco M, Arribas IM. Clinical and radiologic outcomes of surgical and conservative treatment of type III acromioclavicular joint injury. *J Shoulder Elbow Surg* 2006;15:300-305.
- Urist MR. Complete dislocation of the acromioclavicular joint: the nature of the traumatic lesion and effective methods of treatment with an analysis of 41 cases. *J Bone Joint Surg* 1946;28:813-837.
- Guy DK, Wirth MA, Griffin JL, et al. Reconstruction of chronic and complete dislocations of the acromioclavicular joint. *Clin Orthop Relat Res* 1998; 347:138-149.
- Urist MR. Complete dislocation of the acromioclavicular joint. *J Bone Joint Surg Am* 1963;45:1750-1753.
- Weaver JK, Dunn HK. Treatment of acromioclavicular injuries, especially complete acromioclavicular separation. *J Bone Joint Surg Am* 1972;54:1187-1194.
- Phillips AM, Smart C, Groom AFG. Acromioclavicular dislocation: conservative or surgical therapy. *Clin Orthop Relat Res* 1998;353:10-17.
- Larsen E, Petersen V. Operative treatment of chronic acromioclavicular dislocation. *Injury* 1987;18:55-56.
- Berson BL, Gilbert MS, Green S. Acromioclavicular dislocations: treatment by transfer of the conjoined tendon and distal end of the coracoid process to the clavicle. *Clin Orthop Relat Res* 1978;135:157-164.
- Rolla PR, Surace MF, Murena L. Arthroscopic treatment of acute acromioclavicular joint dislocation. *Arthroscopy* 2004;20:662-668.
- Murena L, Vulcano E, Ratti C, et al. Arthroscopic treatment of acute acromioclavicular joint dislocation with double flip button. *Knee Surg Sports Traumatol Arthrosc* 2009;17:1511-1515.
- Gerhardt C, Kraus N, Greiner S, et al. Arthroscopic stabilization of acute acromioclavicular joint dislocation. *Orthopade* 2011;40:61-69.
- Fremerey RW, Lobenhoffer P, Bosch U, et al. Surgical treatment of acute, complete acromioclavicular joint dislocation. Indications, technique and results. *Unfallchirurg* 1996;99:341-345.
- Greiner S, Braunsdorf J, Perka C, et al. Mid to long-term results of open acromioclavicular joint reconstruction using polydioxansulfate cerclage augmentation. *Arch Orthop Trauma Surg* 2009;129:735-740.
- Ladermann A, Grosclaude M, Lubbeke A, et al. Acromioclavicular and coracoclavicular cerclage reconstruction for acute acromioclavicular joint dislocations. *J Should Elb Surg* 2010;20:401-408.
- Leidel BA, Braunstein V, Pilotto S, et al. Mid-term outcome comparing temporary K-wire fixation versus PDS augmentation of Rockwood grade III acromioclavicular joint separations. *BMC Res Notes* 2009;2:84.
- Wei HF, Chen YF, Zeng BF, et al. Triple endobutton technique for the treatment of acute complete acromioclavicular joint dislocations: preliminary results. *Int Orthopaedics* 2011;35:555-559.